UpToDate®
Official reprint from UpToDate®
www.uptodate.com © 2023 UpToDate, Inc. and/or its affiliates. All Rights Reserved.

Wolters Kluwer

Patent ductus arteriosus in preterm infants: Pathophysiology, clinical manifestations, and diagnosis

Author: Joseph B Philips III, MD, FAAP
Section Editors: Joseph A Garcia-Prats, MD, David R Fulton, MD
Deputy Editor: Laurie Wilkie, MD, MS

All topics are updated as new evidence becomes available and our peer review process is complete.

Literature review current through: Feb 2023. | **This topic last updated:** Jul 25, 2022.

INTRODUCTION

In the fetus, the ductus arteriosus (DA) is an important vascular connection between the main pulmonary artery and the aorta (figure 1) that diverts blood from the pulmonary artery into the aorta, thereby bypassing the lungs. After birth, the DA undergoes active constriction and eventual obliteration. A patent ductus arteriosus (PDA) occurs when the ductus fails to completely close after delivery. PDA occurs commonly in preterm infants, especially in those with respiratory distress syndrome.

The pathophysiology, clinical features, and diagnosis of PDA in preterm infants are reviewed here. The management of PDA in preterm infants, as well as the diagnosis and treatment of PDA in older infants and children, are discussed separately. (See "Patent ductus arteriosus in preterm infants: Management" and "Clinical manifestations and diagnosis of patent ductus arteriosus in term infants, children, and adults".)

FETAL AND TRANSITIONAL DUCTAL CIRCULATION

Circulatory transition at birth — In the fetus, the right ventricle accommodates approximately 65 percent of the total cardiac output. The pulmonary vasculature is constricted, resulting in a high vascular resistance within the pulmonary bed. In contrast, the placenta creates a very low resistance bed arising from the aorta, and systemic vascular resistance is low. As a result, the majority of blood exiting from the right ventricle passes right-to-left across the

ductus arteriosus (DA) into the descending aorta and onto the placenta (figure 2 and figure 3). (See "Physiologic transition from intrauterine to extrauterine life", section on 'Fetus'.)

With the onset of respiration after delivery, the lungs expand and the systemic oxygen saturation rises, resulting in pulmonary vasodilatation and a drop in pulmonary vascular resistance. At the same time, systemic resistance rises with placental removal. These factors lead to a sudden reversal of blood flow in the DA from right-to-left to left-to-right shunting with concomitant increase in left ventricular output [1]. (See "Physiologic transition from intrauterine to extrauterine life", section on 'Transition at delivery'.)

Patency of the ductus — The fetal ductus is kept patent by low arterial oxygen content and has a diameter similar in size to that of the descending aorta (figure 1) [2]. Ductal patency also is influenced by vasodilators, including prostaglandins and nitric oxide.

At birth, the rise in systemic oxygen tension with the onset of breathing results in active constriction of the ductus, although the mechanisms for this response are not fully understood. In addition, circulating levels of the vasodilator prostaglandin E_2 are decreased after delivery because of both reduced production following removal of the placenta and increased pulmonary clearance [3]. The predominance of constricting agents results in ductal constriction. (See "Clinical manifestations and diagnosis of patent ductus arteriosus in term infants, children, and adults", section on 'Ductal constriction'.)

The role of prostaglandins in maintaining ductal patency provides the rationale for the use of inhibitors of prostaglandin synthesis (eg, indomethacin and ibuprofen) in the treatment of PDA. antenatal administration of indomethacin also can induce intrauterine ductal constriction. In two case series, fetal echocardiography detected ductal constriction in approximately one-half of the fetuses whose mothers received antenatal indomethacin treatment [4,5]. In one of these reports, ductal constriction occurred in 70 percent of fetuses after 31 weeks gestation and was reversed with discontinuation of the drug [5]. (See "Safety of rheumatic disease medication use during pregnancy and lactation", section on 'NSAIDs'.)

Permanent closure — The initial sustained constriction of the ductus is the first step in permanent anatomic closure. The closure is thought to begin at the pulmonary end of the ductus and proceeds toward the aortic end [6].

Gestational age (GA) has a major impact upon the rate of ductal closure:

- **Term infants** – At term, constriction of the ductus results in functional hemodynamic closure in 50 percent of infants within 24 hours after birth, in 90 percent at 48 hours, and

in virtually all patients after 72 hours [7]. (See "Clinical manifestations and diagnosis of patent ductus arteriosus in term infants, children, and adults", section on 'Ductal constriction'.)

- **Preterm infants** – Ductal closure is delayed in preterm infants and the risk of PDA is inversely proportional to GA. The higher incidence of PDA in preterm infants may be explained by the effect of prematurity on the regulators of ductal tone (eg, oxygen) [8-11].

Complete anatomic closure usually takes two to three weeks but may take up to several months. Following initial functional constriction, the proliferation and infolding of endothelial cells and migration of undifferentiated smooth muscle cells result in the obliteration of the ductal lumen and conversion to the ligamentum arteriosum [8,12]. These histologic changes depend upon the initial ductal constriction and the resultant hypoxia within the ductal wall. Hypoxia of the inner vessel wall causes loss of cells from the muscle media and production of vascular endothelial growth factor (VEGF). VEGF stimulates endothelial cell proliferation that leads to formation of mounds in the intima that occlude the lumen [9,13-15].

Reopening — The histologic changes following constriction of the DA occur rapidly in term infants and prevent subsequent reopening. However, in preterm infants, the ductus can reopen after closure that occurs either spontaneously or following indomethacin treatment [16,17]. The reopening of the DA may be due to the same effects of prematurity that blunt the ductal response to factors that promote initial constriction at the time of delivery. In one study of 77 preterm infants who had complete clinical closure of a PDA after indomethacin treatment, a clinically significant PDA recurred in 23 percent of the patients [18]. The rate of reopening increased with decreasing GA, occurring more frequently in infants less than 27 weeks gestation than in those 27 to 33 weeks (37 versus 11 percent).

CONSEQUENCES OF A PDA

Overview — Blood flow through a PDA in preterm infants results in a left-to-right shunting of blood from the aorta into the pulmonary arteries leading to increased flow through the pulmonary circulation and potential hypoperfusion of the systemic circulation. Radionuclide studies demonstrate pulmonary blood flow can be up to three times greater than that of the systemic blood flow [19]. The physiologic consequences of this "ductal steal" depend upon the size of the shunt and the response of the heart, lungs, and other organs to the shunt. It should be noted that shunting through the ductus arteriosus is normal during fetal life and is important during the transition at birth. In instances where there is persistent pulmonary hypertension, the ductus can relieve excess stress on the heart by shunting blood right-to-left

from the pulmonary artery to the aorta. In cases of ductal-dependent congenital heart disease the ductus is vital for supporting circulation and reducing the right ventricular afterload. However, there may be deleterious effects of a PDA when there is excessive left-to-right shunting from the aorta into the pulmonary artery with resulting pulmonary overcirculation and reduced systemic perfusion with significant shunting.

Clinically meaningful findings are due to a hemodynamically significant PDA (see 'Hemodynamically significant PDA' below) and include the following:

- Pulmonary edema
- Pulmonary hemorrhage
- Bronchopulmonary dysplasia (BPD)
- Intraventricular hemorrhage (IVH)
- Necrotizing enterocolitis (NEC)

Pulmonary effects — In preterm infants, a symptomatic PDA is associated with increased risk of pulmonary edema, pulmonary hemorrhage, bronchopulmonary dysplasia, and a decrease in pulmonary function. PDA closure eliminates the left-to-right shunting of blood and improves pulmonary compliance and ventilation [20-23]. (See 'Hemodynamically significant PDA' below.)

- **Pulmonary edema** — Infants with PDA are at risk for pulmonary edema. Proposed underlying mechanisms include increased filtration of lung fluid into the interstitium from increased pulmonary blood flow and/or increased left atrial pressure loading with secondary pulmonary venous hypertension (image 1).

- **Pulmonary hemorrhage** — Larger PDAs with increased pulmonary blood flow and ductal shunting are associated with pulmonary hemorrhage. In a study of 126 infants born before 30 weeks gestation, 12 patients with pulmonary hemorrhage compared with those without pulmonary hemorrhage had greater median PDA diameter (2 versus 0.5 mm) and pulmonary blood flow (326 versus 237 mL/kg per minute) [24]. Ductal diameter measured at five hours of age also was greater in the infants who subsequently developed pulmonary hemorrhage.

- **Bronchopulmonary dysplasia** — A hemodynamically significant PDA may be associated with the development of subsequent BPD [25-27].

  Support for the role of PDA in the development of BPD was provided by a large case series of 865 very low birth weight (VLBW) infants (BW <1500 g) who survived to 36 weeks postmenstrual age [27]. A diagnosis of PDA in the first week after birth was associated with a 4.5-fold increase in BPD [27]. The risk of BPD and long-term pulmonary sequelae

may be related to the duration of ductal patency, even when the PDA is asymptomatic [28,29]. (See "Bronchopulmonary dysplasia: Definition, pathogenesis, and clinical features".)

Additional evidence regarding the association with hemodynamically significant PDA and BPD were provided by the following:

- A retrospective cohort study of preterm infants (GA <28 weeks) reported symptomatic infants at-risk for BPD (eg, ventilator-dependent) were more likely to undergo surgical ligation [30].
- A smaller case series of VLBW infants (BW <1500 g), surgical ligation was associated with respiratory improvement for infants who received high-frequency ventilation [31].
- Prophylactic indomethacin provided in the first week of life compared with conservative management was associated with a lower incidence of PDA and duration of moderate to large PDA. Multivariate analysis also demonstrated a decreased risk of BPD and BPD or death for infants who received prophylactic indomethacin compared with those with conservative treatment [32].

In contrast, data from the Trial of Indomethacin Prophylaxis in Preterms (TIPP) demonstrated that prophylactic intervention to prevent PDA did not decrease the incidence of BPD [33]. A re-examination of the only trial of prophylactic ductal ligation actually showed a higher risk of BPD in the ligated infants [34]. Thus, while it would be logical to assume that PDA may be a contributing factor to the development of BPD because of the strong association between the two, such a causal link has not fully been established and may not exist.

Systemic and cerebral blood flow effects — Although preterm infants with a PDA have an increased cardiac output, the postductal blood flow is reduced because of left-to-right shunting. Moderate and large ductal steals in infants with PDA result in reduced oxygen delivery and perfusion to vital organs and may contribute to an increased risk of IVH and NEC.

- **Intraventricular hemorrhage** — Moderate or large left-to-right shunts may increase the risk of IVH. Late IVH (occurring after 24 hours of life) is thought to result from ischemia-reperfusion injury due to cardiac output that is initially low followed by rapid augmentation when pulmonary vascular resistance (PVR) falls [35]. Infants with significant PDAs also have reduced cerebral blood flow and oxygenation, but data are lacking demonstrating an association of these findings with IVH [36,37].

Data from the TIPP study showed the risk of severe IVH was decreased in the group who received prophylactic indomethacin for PDA closure compared with the placebo group (9 versus 13 percent) [38]. However, there was no difference in the rate of neurosensory impairment for survivors in both groups at a corrected age of 18 months.

- **Necrotizing enterocolitis** — In a study of VLBW infants, the rate of NEC in the prophylactically ligated group was lower than the control group (8 versus 30 percent) [39]. These results may be due to a lower abdominal aortic blood flow in infants due to a significant ductal steal in infants with a hemodynamically significant PDA compared with infants with no or less significant PDAs [39,40]. However, a systematic review of the literature did not observe any difference in NEC rates between prophylactically treated infants and controls [41]. (See "Neonatal necrotizing enterocolitis: Pathology and pathogenesis", section on 'Circulatory instability'.)

- **Hypotension** — Moderate or large PDAs are associated with clinically significant hypotension requiring pharmacotherapy intervention [42-44]. In some cases after surgical ligation, hypotension is refractory to vasopressor therapy and may be due to low cortisol levels and impaired vascular tone [45,46].

RISK FACTORS

The risk of PDA increases with decreasing gestational age (GA) and birth weight (BW), and chromosomal abnormalities [47-51]. In very low birth weight (VLBW) infants (BW <1500 g), the incidence of PDA is approximately 30 percent [52]. For healthy infants greater than 30 weeks gestation, the ductus typically closes by the fourth day of life [53]. However, two-thirds of ill infants less than 30 weeks gestation will have a persistent PDA through the fourth day of life and closure is especially delayed for moderate to large PDAs [16,54]. Closure is also less likely to occur in infants who have neonatal respiratory distress syndrome, who did not receive antenatal corticosteroids, who have evidence of metabolic acidosis or with exposure to chorioamnionitis [16,55,56].

CLINICAL FEATURES

The clinical features of PDA are dependent on the magnitude of the shunt. Those with hemodynamically significant PDAs will exhibit findings of pulmonary overcirculation and left heart overload. These patients typically develop signs during the first two to three days after birth. Clinical findings may develop earlier in infants treated with surfactant because the

reduction in pulmonary vascular resistance (PVR) associated with improved lung function results in increased left-to-right shunting [57-59]. Heart failure may rarely develop later in the first week. In a few patients, asymptomatic PDA can persist with closure occurring after 10 days of age [16].

Heart murmur — In patients with moderate to large PDAs, cardiac auscultation detects a murmur often heard over the entire precordium, but best heard in the left infraclavicular region and upper left sternal border. At delivery with high PVR, the murmur initially may be heard only in systole because aortic pressure is greater than pulmonary pressure only in systole and not in diastole. As PVR and pulmonary artery pressure (PAP) fall, aortic pressure is higher than PAP during both systole and diastole, producing continuous flow through the ductus and the continuous (machinery) murmur typically associated with a PDA (movie 1).

For patients with a small PDA, a murmur may not be detected. Occasionally, even a larger PDA is clinically "silent" with absence of a murmur, especially in the first three days after birth [60,61]. In these cases, if there is a hemodynamically significant PDA, there may be signs associated with pulmonary overcirculation and left ventricular overload depending on the degree of PVR.

Findings associated with hemodynamically significant PDA — Clinical findings associated with a hemodynamically significant PDA include:

- Signs of increased pulmonary circulation, including tachypnea, apnea, increased carbon dioxide retention, and/or increased requirements for respiratory support including mechanical ventilation. Chest radiography will demonstrate increased pulmonary vascular markings and/or edema (image 1).
- Signs of left ventricular overload include prominent left ventricular impulse and enlarged heart on chest radiograph (image 1).
- Systemic circulatory findings include bounding pulses and a widened pulse pressure that is greater than 25 mmHg or a difference between the systolic and diastolic blood pressure (BP) that exceeds half of the value of the systolic BP. Diastolic BP is typically low.
- Other clinical findings due to poor systemic perfusion include acidosis, oliguria, and abdominal distension.

However, no single finding is specific for a PDA. Similar findings can occur with other cardiac lesions, such as an aortic-pulmonary window or an arteriovenous fistula.

Associated complications — Complications of prematurity that occur more commonly among infants with a hemodynamically significant PDA include (see 'Consequences of a PDA' above):

- Pulmonary edema
- Bronchopulmonary dysplasia (BPD) [34]
- Necrotizing enterocolitis (NEC) [39]
- Heart failure
- Intraventricular hemorrhage (IVH) [38]
- Prolonged ventilator and/or oxygen support
- Acute kidney injury [62,63]

DIAGNOSIS

The diagnosis of PDA is usually suspected by its characteristic clinical findings (see 'Clinical features' above) and confirmed by echocardiography. The combination of two-dimensional echocardiographic imaging and Doppler color flow mapping is both sensitive and specific for the identification of PDA (movie 2 and movie 3) [64].

Echocardiogram — At our institution, an echocardiogram is performed to confirm the presence of a clinically significant PDA before initiating therapy. Other centers, especially those in resource-limited settings without readily available onsite echocardiography, may elect to treat presumptively based on clinical findings. In these settings, echocardiography is performed only if there is a contraindication to the use of indomethacin or ibuprofen therapy, when there is no response to medical therapy, or there is a recurrence of findings after medical therapy. (See "Clinical manifestations and diagnosis of patent ductus arteriosus in term infants, children, and adults", section on 'Echocardiography'.)

In preterm infants without a murmur or other physical findings suggestive of PDA, but with an unexplained deterioration in respiratory status, an echocardiogram is necessary to determine whether a "silent" PDA is present. (See 'Clinical features' above.)

Hemodynamically significant PDA — Because the interventions used to close PDA can have significant adverse effects, the decision to intervene should be based upon a hemodynamically significant PDA, which if left untreated leads to pulmonary overcirculation (pulmonary edema), and systemic undercirculation (oliguria and metabolic acidosis) (see 'Consequences of a PDA' above and 'Associated complications' above).

In our practice, the diagnosis of a hemodynamically significant PDA uses both clinical findings and echocardiographic measurements to classify the severity of PDA and guide management

decisions [51,65].

Clinical findings include:

- Need for oxygenation and respiratory support
- Evidence of oliguria
- Presence and degree of acidosis
- Physical findings of wide pulse pressure, suggestive of pulmonary edema (rales)
- Episodes of hypotension requiring pharmacotherapeutic intervention
- Cardiomegaly based on chest radiograph (see 'Chest radiograph' below)

The echocardiographic findings used to define a hemodynamically significant include [51,66]:

- PDA diameter that exceeds 1.4 mm [51,66-69]. However, transductal diameter cannot be used as the sole measure of a significant PDA and measurements of systemic perfusion are also needed [70]. In addition, PDA diameter may need to be adjusted to the relative size of the patient especially in the smallest infants. Adjustments vary amongst centers and include corrections based on body surface area or in relation with the left pulmonary artery diameter [66,70]. A PDA:LPA flow ratio defines large (≥1), moderate (<1 but ≥0.5), and small (<0.5) PDAs (movie 2 and movie 3) [71,72].

- Additional criteria for estimation of systemic perfusion include one or more of the following. However, criteria vary from center to center, although most centers agree that reversed diastolic flow in the descending aorta represents a significant finding of systemic hypoperfusion [66,70]:

  - Reversed diastolic flow in the descending aorta.

  - Ductus flow velocity ≤2.5 m/sec or mean pressure gradient across the ductus ≤8 mmHg.

  - Evaluation of left ventricular output. There is also center variability on how this is measured.

  - Assessment of left ventricular output and evidence of left ventricular or atrial hypertrophy.

Several centers have incorporated these findings to develop PDA scoring systems to guide therapeutic decisions (algorithm 1) [51]. These provide a more precise management approach with the use of objective criteria, thereby decreasing the variability in patient care.

Chest radiograph — Chest radiography may be helpful in the diagnosis and evaluation of PDA in preterm infants, but it is less sensitive and specific than echocardiography. In patients with moderate and large PDAs, the chest radiograph shows increasing cardiac enlargement and pulmonary vascular markings as the left-to-right shunting increases (image 1). The electrocardiogram is not helpful in the diagnosis of PDA in preterm infants.

Biomarkers — Biomarkers such as B-type natriuretic peptide (BNP), the inactive N-terminal pro-BNP, and troponin T have been proposed as useful in the diagnosis and management of PDA [73-76]. However, a review of the literature found that the sensitivity and specificity of these tests vary in different populations and sites [77]. As a result, further study is needed prior to the routine use of BNP or other biomarkers to diagnose and manage PDA in preterm infants. In our center, we do not use BNP to make a diagnosis of PDA.

DIFFERENTIAL DIAGNOSIS

Although very uncommon, other diagnoses of continuous murmurs include systemic arteriovenous malformations, fistula, and aortic-pulmonary window. Although very rare, combined aortic stenosis and regurgitation and combined pulmonic stenosis and regurgitation will have murmurs through diastole and systole described as a "to-and-fro" murmur rather than one with a continuous quality as seen in those with a PDA. PDA is distinguished from these conditions based on physical findings (quality and location of the murmur) and echocardiography. (See "Clinical manifestations and diagnosis of patent ductus arteriosus in term infants, children, and adults", section on 'Differential diagnosis'.)

SCREENING

Universal screening for PDA in extremely preterm (EPT) infants (gestational age [GA] <28 weeks) has been proposed as a strategy to reduce morbidity and mortality associated with PDA in this population. However, the evidence remains inconclusive. As a result, in our practice, we continue to perform screening echocardiography selectively only if there are clinical signs of PDA.

The impact of universal screening was investigated in a study of 1513 EPT infants from the EPIPAGE 2 cohort, a prospective population-based French study [78]. Screening echocardiogram was performed in 56 percent of patients (n=847), whereas 44 percent (n=666) did not undergo screening. In propensity score analysis, PDA screening was associated with lower in-hospital mortality (14 versus 18 percent; odds ratio [OR] 0.73, 95% CI 0.54 to 0.98) and a lower incidence

of pulmonary hemorrhage (5.6 versus 8.9 percent; OR 0.60, 95% CI 0.38 to 0.95). The higher mortality in the non-screened group was primarily observed in untreated infants; however, it is unclear whether all of these patients had a PDA. Rates of NEC, severe BPD, and severe cerebral injury were similar in both groups.

A follow-up study reported neurodevelopmental outcomes at 5.5 years in 71 percent of surviving infants from the original propensity score matched cohort of EPIPAGE 2 [79]. Rates of moderate to severe neurodevelopmental impairment (NDI) were similar in screened and non-screened infants (24 versus 28 percent, respectively). On standardized testing, children in the screened group scored higher on two domains of intelligence, but full-scale intelligence quotients were similar in both groups. There were few deaths in either group after discharge from the initial neonatal hospitalization. Overall, more infants in the screened group survived to age 5.5 years without moderate to severe NDI (65 versus 59 percent), though this finding had borderline statistical significance (OR 1.3, 95% CI 1.0-1.68).

The findings of EPIPAGE 2 are promising; however, given the observational nature of these data, it is possible that some of the observed differences between screened and non-screened infants in these studies may be explained by selection bias. These results should be confirmed in randomized trials before universal screening is adopted into routine clinical practice. In particular, the cost-benefit of universal versus selective screening remains uncertain.

SUMMARY AND RECOMMENDATIONS

- **Definition and physiology** – The ductus arteriosus (DA) is a fetal vascular connection between the main pulmonary artery and the aorta that normally closes soon after birth (figure 1). A patent ductus arteriosus (PDA) occurs when the ductus fails to completely close after delivery. (See 'Fetal and transitional ductal circulation' above.)

  In patients with a PDA, the left-to-right shunting of blood results in an excessive blood flow through the pulmonary circulation and potential hypoperfusion of the systemic circulation, which is dependent on the ratio of pulmonary vascular resistance (PVR) to systemic vascular resistance. The physiologic consequences of this "ductal steal" depend upon the size of the shunt and the response of the heart, lungs, and other organs to the shunt.

- **Risk factors** – Ductal closure is delayed in preterm infants and the risk of PDA is inversely proportional to gestational age (GA). Respiratory illness and antenatal administration of

nonsteroidal antiinflammatory drugs (eg, indomethacin and ibuprofen) are also associated with increased risk of PDA. (See 'Risk factors' above.)

- **Clinical features** – The following clinical features are seen in the majority of preterm infants with a hemodynamically significant PDA (see 'Findings associated with hemodynamically significant PDA' above):
  - Heart murmur – In most infants with a moderate to large PDA shunt, cardiac auscultation demonstrates a heart murmur heard over the entire precordium, but best heard in the left infraclavicular region and upper left sternal border. Immediately after delivery when PVR is high, the murmur initially may be heard only in systole. As PVR falls, the murmur can be heard in systole and diastole, producing the characteristic continuous PDA murmur (movie 1). (See 'Heart murmur' above.)
  - Cardiovascular findings indicative of left ventricular overload and pulmonary runoff include prominent left ventricular impulse, bounding pulses, widened pulse pressure, systemic hypotension, and chest radiograph finding of cardiac enlargement.
  - Findings of pulmonary overcirculation including tachypnea, apnea, increased carbon dioxide retention, need for respiratory support, and chest radiographic findings of increased pulmonary vascular markings.
  - Other findings may include oliguria and metabolic acidosis.
- **Diagnosis** – The diagnosis of PDA is usually suggested based upon the characteristic clinical findings (eg, heart murmur) and confirmed by echocardiography (movie 2 and movie 3). (See 'Diagnosis' above.)
- **Consequences and complications of PDA** – Infants with hemodynamically significant PDA have clinical and echocardiographic findings that provide evidence of pulmonary overcirculation (pulmonary edema) and left-to-right shunting, left ventricular overload and systemic undercirculation (eg, oliguria and metabolic acidosis). These infants are at risk for pulmonary edema and hemorrhage, bronchopulmonary dysplasia (BPD), intraventricular hemorrhage (IVH), and episodes of significant hypotension. (See 'Consequences of a PDA' above and 'Associated complications' above.)

Use of UpToDate is subject to the Terms of Use.

REFERENCES

1. Jain A, El-Khuffash AF, Kuipers BCW, et al. Left Ventricular Function in Healthy Term Neonates During the Transitional Period. J Pediatr 2017; 182:197.
2. Smith GC. The pharmacology of the ductus arteriosus. Pharmacol Rev 1998; 50:35.
3. Clyman RI, Mauray F, Roman C, et al. Circulating prostaglandin E2 concentrations and patent ductus arteriosus in fetal and neonatal lambs. J Pediatr 1980; 97:455.
4. Moise KJ Jr. Effect of advancing gestational age on the frequency of fetal ductal constriction in association with maternal indomethacin use. Am J Obstet Gynecol 1993; 168:1350.
5. Vermillion ST, Scardo JA, Lashus AG, Wiles HB. The effect of indomethacin tocolysis on fetal ductus arteriosus constriction with advancing gestational age. Am J Obstet Gynecol 1997; 177:256.
6. Gittenberger-de Groot AC, Strengers JL, Mentink M, et al. Histologic studies on normal and persistent ductus arteriosus in the dog. J Am Coll Cardiol 1985; 6:394.
7. Gentile R, Stevenson G, Dooley T, et al. Pulsed Doppler echocardiographic determination of time of ductal closure in normal newborn infants. J Pediatr 1981; 98:443.
8. Clyman RI, Waleh N, Black SM, et al. Regulation of ductus arteriosus patency by nitric oxide in fetal lambs: the role of gestation, oxygen tension, and vasa vasorum. Pediatr Res 1998; 43:633.
9. Clyman RI, Chan CY, Mauray F, et al. Permanent anatomic closure of the ductus arteriosus in newborn baboons: the roles of postnatal constriction, hypoxia, and gestation. Pediatr Res 1999; 45:19.
10. Clyman RI. Ductus arteriosus: current theories of prenatal and postnatal regulation. Semin Perinatol 1987; 11:64.
11. Clyman RI, Mauray F, Roman C, et al. Effect of gestational age on ductus arteriosus response to circulating prostaglandin E2. J Pediatr 1983; 102:907.
12. Gittenberger-de Groot AC. Persistent ductus arteriosus: most probably a primary congenital malformation. Br Heart J 1977; 39:610.
13. Sandner P, Wolf K, Bergmaier U, et al. Induction of VEGF and VEGF receptor gene expression by hypoxia: divergent regulation in vivo and in vitro. Kidney Int 1997; 51:448.
14. Tuder RM, Flook BE, Voelkel NF. Increased gene expression for VEGF and the VEGF receptors KDR/Flk and Flt in lungs exposed to acute or to chronic hypoxia. Modulation of gene expression by nitric oxide. J Clin Invest 1995; 95:1798.
15. Waleh N, Seidner S, McCurnin D, et al. Anatomic closure of the premature patent ductus arteriosus: The role of CD14+/CD163+ mononuclear cells and VEGF in neointimal mound formation. Pediatr Res 2011; 70:332.

16. Koch J, Hensley G, Roy L, et al. Prevalence of spontaneous closure of the ductus arteriosus in neonates at a birth weight of 1000 grams or less. Pediatrics 2006; 117:1113.
17. Quinn D, Cooper B, Clyman RI. Factors associated with permanent closure of the ductus arteriosus: a role for prolonged indomethacin therapy. Pediatrics 2002; 110:e10.
18. Weiss H, Cooper B, Brook M, et al. Factors determining reopening of the ductus arteriosus after successful clinical closure with indomethacin. J Pediatr 1995; 127:466.
19. Vick GW 3rd, Satterwhite C, Cassady G, et al. Radionuclide angiography in the evaluation of ductal shunts in preterm infants. J Pediatr 1982; 101:264.
20. Stefano JL, Abbasi S, Pearlman SA, et al. Closure of the ductus arteriosus with indomethacin in ventilated neonates with respiratory distress syndrome. Effects of pulmonary compliance and ventilation. Am Rev Respir Dis 1991; 143:236.
21. Yeh TF, Thalji A, Luken L, et al. Improved lung compliance following indomethacin therapy in premature infants with persistent ductus arteriosus. Chest 1981; 80:698.
22. Gerhardt T, Bancalari E. Lung compliance in newborns with patent ductus arteriosus before and after surgical ligation. Biol Neonate 1980; 38:96.
23. Szymankiewicz M, Hodgman JE, Siassi B, Gadzinowski J. Mechanics of breathing after surgical ligation of patent ductus arteriosus in newborns with respiratory distress syndrome. Biol Neonate 2004; 85:32.
24. Kluckow M, Evans N. Ductal shunting, high pulmonary blood flow, and pulmonary hemorrhage. J Pediatr 2000; 137:68.
25. Todd DA, Jana A, John E. Chronic oxygen dependency in infants born at 24-32 weeks' gestation: the role of antenatal and neonatal factors. J Paediatr Child Health 1997; 33:402.
26. Hagan R, Minutillo C, French N, et al. Neonatal chronic lung disease, oxygen dependency, and a family history of asthma. Pediatr Pulmonol 1995; 20:277.
27. Marshall DD, Kotelchuck M, Young TE, et al. Risk factors for chronic lung disease in the surfactant era: a North Carolina population-based study of very low birth weight infants. North Carolina Neonatologists Association. Pediatrics 1999; 104:1345.
28. Yanowitz TD, Yao AC, Pettigrew KD, et al. Postnatal hemodynamic changes in very-low-birthweight infants. J Appl Physiol (1985) 1999; 87:370.
29. Saldeño YP, Favareto V, Mirpuri J. Prolonged persistent patent ductus arteriosus: potential perdurable anomalies in premature infants. J Perinatol 2012; 32:953.
30. Weisz DE, Mirea L, Rosenberg E, et al. Association of Patent Ductus Arteriosus Ligation With Death or Neurodevelopmental Impairment Among Extremely Preterm Infants. JAMA Pediatr 2017; 171:443.

31. Hsu KH, Wong P, Ram Kumar S, et al. Predictors of Respiratory Improvement 1 Week after Ligation of Patent Ductus Arteriosus in Preterm Infants. J Pediatr 2019; 205:49.
32. Liebowitz M, Clyman RI. Prophylactic Indomethacin Compared with Delayed Conservative Management of the Patent Ductus Arteriosus in Extremely Preterm Infants: Effects on Neonatal Outcomes. J Pediatr 2017; 187:119.
33. Schmidt B, Roberts RS, Fanaroff A, et al. Indomethacin prophylaxis, patent ductus arteriosus, and the risk of bronchopulmonary dysplasia: further analyses from the Trial of Indomethacin Prophylaxis in Preterms (TIPP). J Pediatr 2006; 148:730.
34. Clyman R, Cassady G, Kirklin JK, et al. The role of patent ductus arteriosus ligation in bronchopulmonary dysplasia: reexamining a randomized controlled trial. J Pediatr 2009; 154:873.
35. Kluckow M, Evans N. Low superior vena cava flow and intraventricular haemorrhage in preterm infants. Arch Dis Child Fetal Neonatal Ed 2000; 82:F188.
36. Martin CG, Snider AR, Katz SM, et al. Abnormal cerebral blood flow patterns in preterm infants with a large patent ductus arteriosus. J Pediatr 1982; 101:587.
37. Lemmers PM, Toet MC, van Bel F. Impact of patent ductus arteriosus and subsequent therapy with indomethacin on cerebral oxygenation in preterm infants. Pediatrics 2008; 121:142.
38. Schmidt B, Davis P, Moddemann D, et al. Long-term effects of indomethacin prophylaxis in extremely-low-birth-weight infants. N Engl J Med 2001; 344:1966.
39. Cassady G, Crouse DT, Kirklin JW, et al. A randomized, controlled trial of very early prophylactic ligation of the ductus arteriosus in babies who weighed 1000 g or less at birth. N Engl J Med 1989; 320:1511.
40. Shimada S, Kasai T, Konishi M, Fujiwara T. Effects of patent ductus arteriosus on left ventricular output and organ blood flows in preterm infants with respiratory distress syndrome treated with surfactant. J Pediatr 1994; 125:270.
41. Ohlsson A, Shah SS. Ibuprofen for the prevention of patent ductus arteriosus in preterm and/or low birth weight infants. Cochrane Database Syst Rev 2020; 1:CD004213.
42. Liebowitz M, Koo J, Wickremasinghe A, et al. Effects of Prophylactic Indomethacin on Vasopressor-Dependent Hypotension in Extremely Preterm Infants. J Pediatr 2017; 182:21.
43. Bouissou A, Rakza T, Klosowski S, et al. Hypotension in preterm infants with significant patent ductus arteriosus: effects of dopamine. J Pediatr 2008; 153:790.
44. Giliberti P, De Leonibus C, Giordano L, Giliberti P. The physiopathology of the patent ductus arteriosus. J Matern Fetal Neonatal Med 2009; 22 Suppl 3:6.

45. Noori S, McNamara P, Jain A, et al. Catecholamine-resistant hypotension and myocardial performance following patent ductus arteriosus ligation. J Perinatol 2015; 35:123.
46. Clyman RI, Wickremasinghe A, Merritt TA, et al. Hypotension following patent ductus arteriosus ligation: the role of adrenal hormones. J Pediatr 2014; 164:1449.
47. Ellison RC, Peckham GJ, Lang P, et al. Evaluation of the preterm infant for patent ductus arteriosus. Pediatrics 1983; 71:364.
48. Furzan JA, Reisch J, Tyson JE, et al. Incidence and risk factors for symptomatic patent ductus arteriosus among inborn very-low-birth-weight infants. Early Hum Dev 1985; 12:39.
49. Mouzinho AI, Rosenfeld CR, Risser R. Symptomatic patent ductus arteriosus in very-low-birth-weight infants: 1987-1989. Early Hum Dev 1991; 27:65.
50. Reller MD, Lorenz JM, Kotagal UR, et al. Hemodynamically significant PDA: an echocardiographic and clinical assessment of incidence, natural history, and outcome in very low birth weight infants maintained in negative fluid balance. Pediatr Cardiol 1985; 6:17.
51. Hamrick SEG, Sallmon H, Rose AT, et al. Patent Ductus Arteriosus of the Preterm Infant. Pediatrics 2020; 146.
52. Lemons JA, Bauer CR, Oh W, et al. Very low birth weight outcomes of the National Institute of Child health and human development neonatal research network, January 1995 through December 1996. NICHD Neonatal Research Network. Pediatrics 2001; 107:E1.
53. Reller MD, Rice MJ, McDonald RW. Review of studies evaluating ductal patency in the premature infant. J Pediatr 1993; 122:S59.
54. Dudell GG, Gersony WM. Patent ductus arteriosus in neonates with severe respiratory disease. J Pediatr 1984; 104:915.
55. Kindler A, Seipolt B, Heilmann A, et al. Development of a Diagnostic Clinical Score for Hemodynamically Significant Patent Ductus Arteriosus. Front Pediatr 2017; 5:280.
56. Green CA, Westreich D, Laughon MM, et al. Association of chorioamnionitis and patent ductus arteriosus in a national U.S. cohort. J Perinatol 2021; 41:119.
57. Seppänen M, Kääpä P, Kero P. Acute effects of synthetic surfactant replacement on pulmonary blood flow in neonatal respiratory distress syndrome. Am J Perinatol 1994; 11:382.
58. Clyman RI, Jobe A, Heymann M, et al. Increased shunt through the patent ductus arteriosus after surfactant replacement therapy. J Pediatr 1982; 100:101.
59. Kääpä P, Seppänen M, Kero P, Saraste M. Pulmonary hemodynamics after synthetic surfactant replacement in neonatal respiratory distress syndrome. J Pediatr 1993; 123:115.

60. Hammerman C, Strates E, Valaitis S. The silent ductus: its precursors and its aftermath. Pediatr Cardiol 1986; 7:121.
61. Skelton R, Evans N, Smythe J. A blinded comparison of clinical and echocardiographic evaluation of the preterm infant for patent ductus arteriosus. J Paediatr Child Health 1994; 30:406.
62. Majed B, Bateman DA, Uy N, Lin F. Patent ductus arteriosus is associated with acute kidney injury in the preterm infant. Pediatr Nephrol 2019; 34:1129.
63. Guillet R, Selewski DT, Griffin R, et al. Relationship of patent ductus arteriosus management with neonatal AKI. J Perinatol 2021; 41:1441.
64. Huhta JC, Cohen M, Gutgesell HP. Patency of the ductus arteriosus in normal neonates: two-dimensional echocardiography versus Doppler assessment. J Am Coll Cardiol 1984; 4:561.
65. Bose CL, Laughon MM. Patent ductus arteriosus: lack of evidence for common treatments. Arch Dis Child Fetal Neonatal Ed 2007; 92:F498.
66. Clyman RI, Liebowitz M, Kaempf J, et al. PDA-TOLERATE Trial: An Exploratory Randomized Controlled Trial of Treatment of Moderate-to-Large Patent Ductus Arteriosus at 1 Week of Age. J Pediatr 2019; 205:41.
67. Hamrick SE, Hansmann G. Patent ductus arteriosus of the preterm infant. Pediatrics 2010; 125:1020.
68. Harling S, Hansen-Pupp I, Baigi A, Pesonen E. Echocardiographic prediction of patent ductus arteriosus in need of therapeutic intervention. Acta Paediatr 2011; 100:231.
69. Kluckow M, Evans N. Early echocardiographic prediction of symptomatic patent ductus arteriosus in preterm infants undergoing mechanical ventilation. J Pediatr 1995; 127:774.
70. de Freitas Martins F, Ibarra Rios D, F Resende MH, et al. Relationship of Patent Ductus Arteriosus Size to Echocardiographic Markers of Shunt Volume. J Pediatr 2018; 202:50.
71. Ramos FG, Rosenfeld CR, Roy L, et al. Echocardiographic predictors of symptomatic patent ductus arteriosus in extremely-low-birth-weight preterm neonates. J Perinatol 2010; 30:535.
72. Thankavel PP, Rosenfeld CR, Christie L, Ramaciotti C. Early echocardiographic prediction of ductal closure in neonates ≤ 30 weeks gestation. J Perinatol 2013; 33:45.
73. Evans N. Diagnosis of the preterm patent ductus arteriosus: clinical signs, biomarkers, or ultrasound? Semin Perinatol 2012; 36:114.
74. Khan SS, Sithisarn T, Bada HS, et al. Urinary NT-proBNP levels and echocardiographic parameters for patent ductus arteriosus. J Perinatol 2017; 37:1319.

75. Rodriguez-Blanco S, Oulego-Erroz I, Gautreaux-Minaya S, et al. Early NT-proBNP levels as a screening tool for the detection of hemodynamically significant patent ductus arteriosus during the first week of life in very low birth weight infants. J Perinatol 2018; 38:881.
76. Asrani P, Aly AM, Jiwani AK, et al. High-sensitivity troponin T in preterm infants with a hemodynamically significant patent ductus arteriosus. J Perinatol 2018; 38:1483.
77. Kulkarni M, Gokulakrishnan G, Price J, et al. Diagnosing significant PDA using natriuretic peptides in preterm neonates: a systematic review. Pediatrics 2015; 135:e510.
78. Rozé JC, Cambonie G, Marchand-Martin L, et al. Association Between Early Screening for Patent Ductus Arteriosus and In-Hospital Mortality Among Extremely Preterm Infants. JAMA 2015; 313:2441.
79. Cambonie G, Rozé JC, Marchand-Martin L, et al. Neurodevelopment at 5 Years of Age According to Early Screening for Patent Ductus Arteriosus in Extremely Preterm Infants. JAMA 2022; 328:71.

Topic 5057 Version 36.0

GRAPHICS

Patent ductus arteriosus

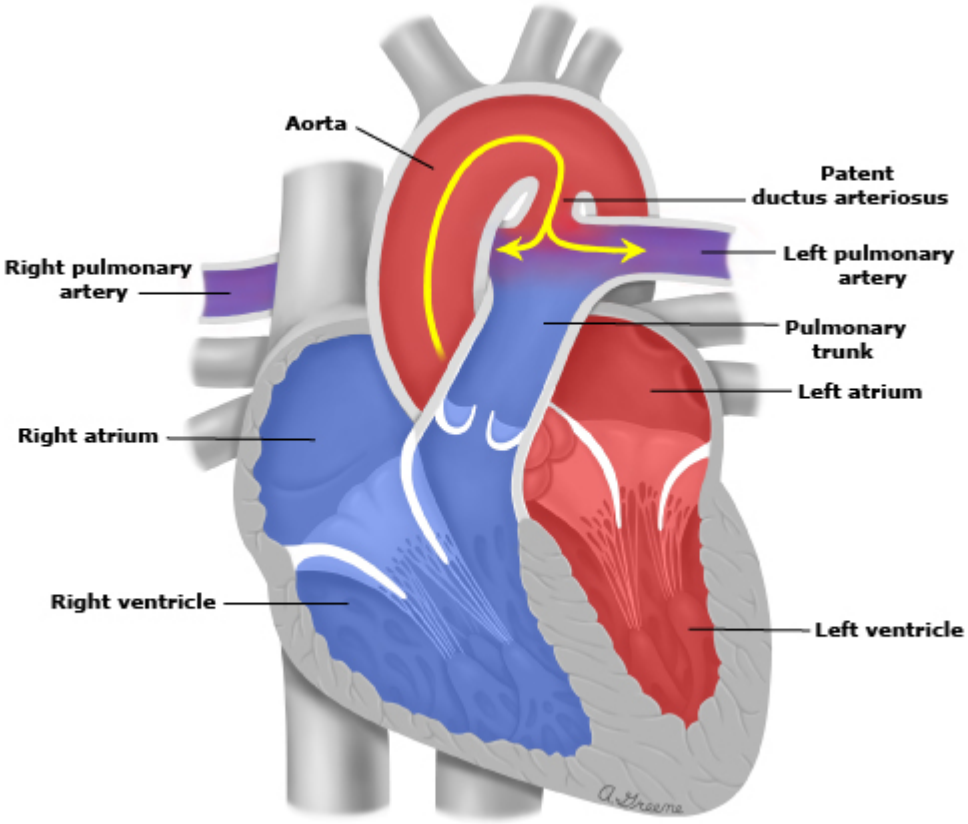

Graphic 65828 Version 2.0

Fetal circulation

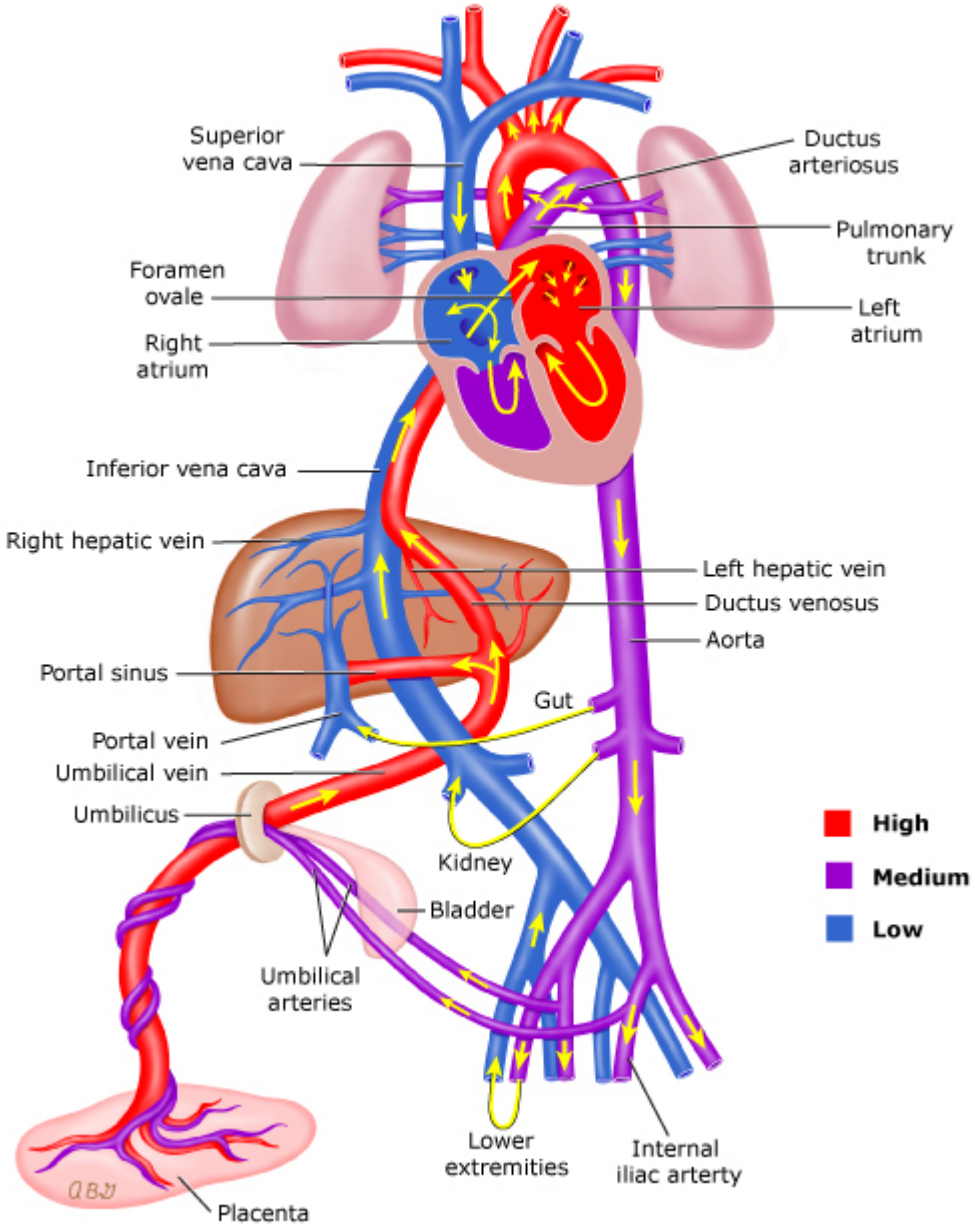

The degree of oxygen saturation is indicated by shading, as explained in the figure key.

Graphic 66765 Version 4.0

Fetal cardiac circulation: Distribution of right (RVO) and left (LVO) ventricular output

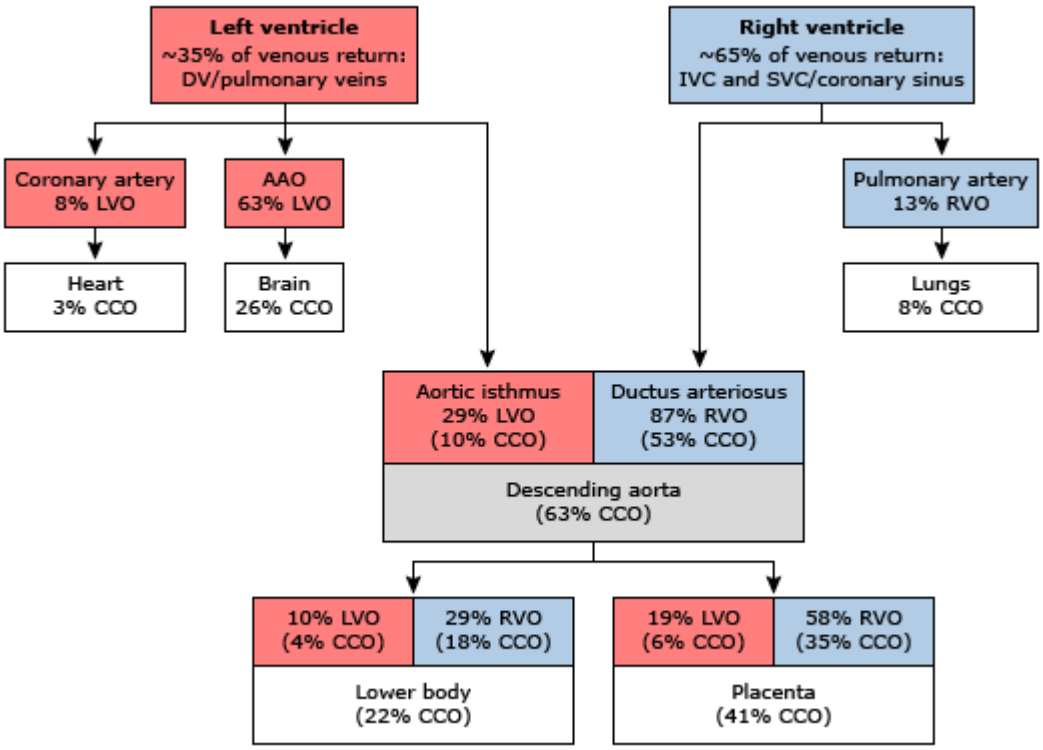

Diagrammatic representation of the fetal circulation. Shown is the distribution of right and left ventricular output (RVO, LVO) and the combined cardiac output (CCO) in the circulation of the fetal lamb. The largest proportion of the CCO is distributed to the placenta for oxygenation. Through preferential streaming, well-oxygenated left ventricular blood supplies the brain and heart while right ventricular blood with lower oxygen content is predominantly distributed to the placenta.

DV: ductus venosus; IVC: inferior vena cava; SVC: superior vena cava; AAO: ascending aorta.

Originally published in: Fetal cardiology. Yagel S, Silverman NH, Gembruch U (Eds), Taylor & Francis, Oxford, UK 2003. p.125. Reproduced with permission from Taylor & Francis. Copyright © 2003. Algorithm updated from: Baschat AA, Gembruch U. Development of fetal cardiac and extracardiac Doppler flows in early gestation. In: Fetal Cardiology, 2nd ed, Yagel S, Silverman NH, Gembruch U (Eds), Informa Healthcare USA, Inc, New York 2009. p.157.

Graphic 70458 Version 6.0

Patent ductus arteriosus in preterm infant before and after indomethacin therapy

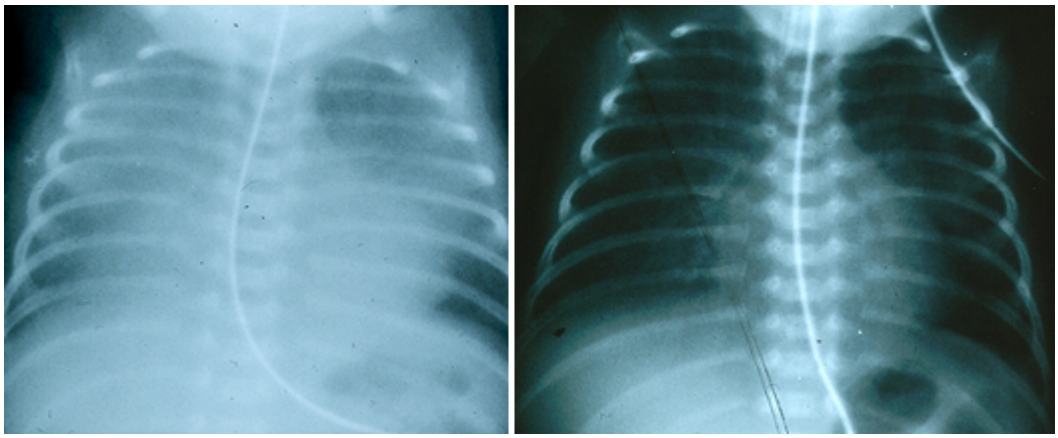

Chest radiographs from a premature infant with a symptomatic patent ductus arteriosus (PDA) before (left panel) and after (right panel) the administration of indomethacin. Prior to therapy, the lungs are opacified due to pulmonary edema resulting from increased blood flow through the PDA; the heart is also mildly enlarged. After therapy, the lung fields are clear and heart size is smaller.

Courtesy of Stephen E Welty, MD.

Graphic 71213 Version 3.0

Management approach of patent ductus arteriosus in preterm infants at the B Women's Hospital

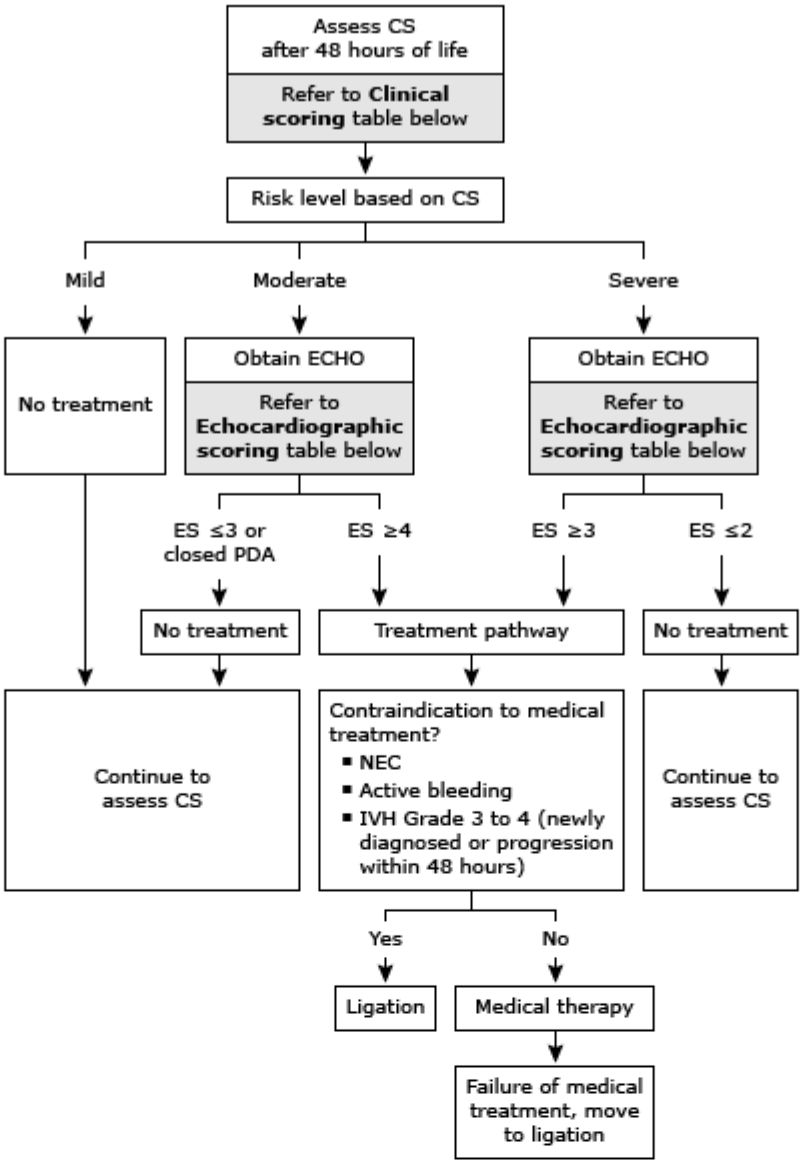

Clinical scoring		
Criterion	**Points**	**Score**
CPAP or FiO_2 ≤40%	1 point	
MAP ≤8 or FiO_2 >40%	2 points	
MAP 9 to 12, or small to moderate pulmonary hemorrhage	3 points	
MAP >12, rescue HFOV, or recurrent or severe pulmonary hemorrhage	4 points	
Cardiovascular		
Widened pulse pressure,* murmur	1 point	
Cardiomegaly or pulmonary edema on chest radiograph	2 points	
Hypotension requiring 1 cardiotropic agent	3 points	
Hypotension requiring >1 cardiotropic agent	4 points	
Renal		
UOP ≥1 mL/kg/hr or Cr ≤1.2	0 points	
UOP <1 mL/kg/hr or Cr >1.2	1 point	
Acidosis		
pH >7.25 and/or BE <-7 (HCO_3- >16)	0 points	

Echocardiographic scoring	
Criterion	**Point**
PDA diameter	
<0.5 mm × √BSA	0 poi
0.5 to 1 mm × √BSA	1 poi
1 to 1.5 mm × √BSA	2 poin
>1.5 mm × √BSA	3 poin
Doppler velocity of Ao-PDA <2 m/s	1 poi
Enlargement of the LA without any other etiology	1 poi
Enlargement of the LV without any other etiology	1 poi
LA hypertension without any other etiology (by flow velocity across PFO or septal bowing left to right)	1 poi
Holodiastolic flow reversal in the abdominal aorta	2 poin
Total:	
Echocardiographic scoring interp	

pH 7.1 to 7.25 and/or BE -7 to -12 (HCO_3^- 11 to 16)	1 point	
pH <7.1 and/or BE < -12 (HCO_3^- <11)	2 points	
Total:		

Clinical score interpretation	
Description	**Range (0 to 11)**
Mild	2 to 3
Moderate	4 to 7
Severe	8 to 11

Description	
Not hemodynamically significant	
Mild	
Moderate	
Severe	

Algorithmic management approach of the neonatal division at the Brigham and Women's Hospital of patent arteriosus for preterm infants (gestational age <29 weeks) based on clinical and echocardiographic scoring

PDA: patent ductus arteriosus; NICU: neonatal intensive care unit; CS: clinical score; ECHO: echocardiogram; echocardiographic score; NEC: necrotizing enterocolitis; IVH: intraventricular hemorrhage; CPAP: continuous airway pressure; FiO2: fraction of inspired oxygen; MAP: mean arterial pressure; HFOV: high frequency oscil ventilation; UOP: urinary output; Cr: creatinine; BE: base excess; HCO_3^-: bicarbonate; BSA: body surface area aortic patent ductus arteriosus; LA: left atrium; LV: left ventricle; PFO: patent foramen ovale.

* Widened pulse pressure defined as diastolic blood pressure less than half of systolic blood pressure.

Reproduced with permission from Terri Gorman, EMD.

Graphic 127115 Version 2.0

Contributor Disclosures

Joseph B Philips III, MD, FAAP No relevant financial relationship(s) with ineligible companies to disclose. **Joseph A Garcia-Prats, MD** No relevant financial relationship(s) with ineligible companies to disclose. **David R Fulton, MD** No relevant financial relationship(s) with ineligible companies to disclose. **Laurie Wilkie, MD, MS** No relevant financial relationship(s) with ineligible companies to disclose.

Contributor disclosures are reviewed for conflicts of interest by the editorial group. When found, these are addressed by vetting through a multi-level review process, and through requirements for references to be provided to support the content. Appropriately referenced content is required of all authors and must conform to UpToDate standards of evidence.

Conflict of interest policy

→